

# Advanced stage juvenile granulosa cell tumor of the ovary detected shortly after term pregnancy

Term gebelik sonrasında saptanan overin ileri evre juvenil granüloza hücreli tümörü

Aysun AYBATLI,<sup>1</sup> Petek BALKANLI KAPLAN<sup>1</sup>

<sup>1</sup>Trakya Üniversitesi Tıp Fakültesi, Kadın Hastalıkları ve Doğum Anabilim Dalı, Edirne

Granulosa cell tumors (GCTs) constitute 70% of all sex-cord stromal tumors of the ovary and 1-2% of all ovarian cancers. A 19-year-old gravida 1, para 1 woman was admitted to our institution with abdominal distension. No ovarian mass had been detected during routine ultrasonographic examinations in our institution throughout her pregnancy, and one year had passed since her delivery by cesarean section. On admission, a painless ovarian mass was detected in the left ovary measuring 7x7x5 cm. Left salpingo-oophorectomy was performed during staging surgery. The case was stage-IIIB according to the FIGO staging system. Pathological examination revealed the diagnosis of juvenile GCT. We report this rare case with the aim of pointing out the possibility of unexpected aggressive behavior of juvenile GCT of the ovary over an approximately one-year period.

**Key words:** Advanced stage; juvenile granulosa cell tumor; ovary.

Granüloza-hücreli tümörler (GHT) overin seks-kord stromal tümörlerinin %70'ini ve tüm over kanserlerinin %1-2'sini oluştururlar. On dokuz yaşında gravida 1, parite 1 hasta merkezimize abdominal distansiyon nedeniyle başvurdu. Bir yıl önce sezeryan ile doğum yapan ve tüm antenatal takipleri kliniğimizde yapılan hastanın o dönemde yapılan periyodik ultrasonografik incelemelerinde herhangi bir overyan kitle izlenmemişti. Acil servise başvurusunda, sol overde 7x7x5 cm ölçülerinde ağrısız kitle tespit edildi. Uygulanan evreleme cerrahisi sonrasında hasta, FIGO evreleme sistemine göre evre IIIB olarak kabul edildi. Patoloji sonucu juvenil GHT olarak bildirildi. Biz olgumuzu yaklaşık olarak son bir yıl içinde gelişip, beklenmedik bir şekilde, agresiv davranış paterni sergilemesi üzerine, overin juvenil GHT'lerinde bu ihtimalin dikkate alınması amacıyla sunduk.

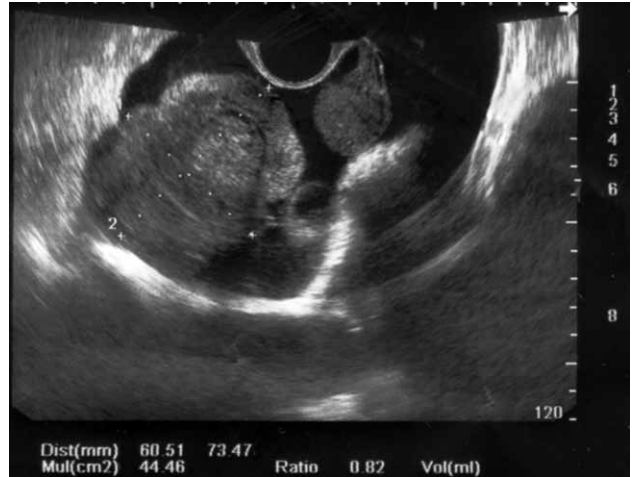**Anahtar sözcükler:** İleri evre; juvenil granüloza hücreli tümör; over.

Granulosa cell tumors (GCTs) are uncommon, accounting for about 1-2% of all ovarian malignancies. Two distinct types exist, known respectively as adult and juvenile.<sup>[1]</sup> Juvenile granulosa cell tumor (JGCT) is one of the rare sex cord stromal tumors of the ovary usually occurring in the first two decades of life.<sup>[1]</sup> It is different from the adult granulosa cell tumor seen in older women with regard to clinical and pathological features as well as biological behavior.<sup>[2]</sup> Most patients with FIGO stage I JGCT have a favorable prognosis

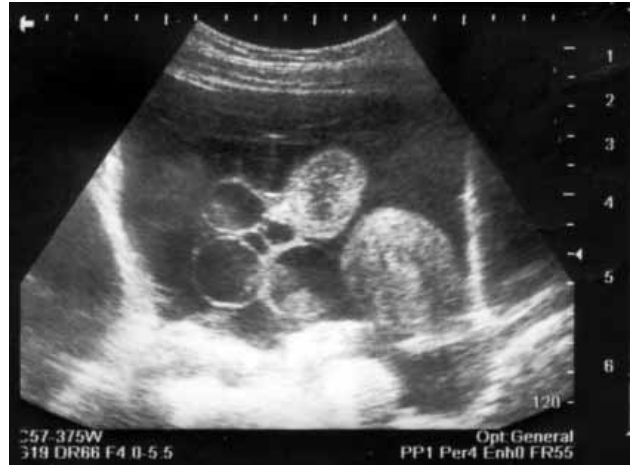when treated with surgery alone. However, the prognosis for advanced-stage JGCT is poor. Few reports have been published related with an aggressive behavior and rapid progression of juvenile GCT, although many series of early stage GCTs have been reported in the literature. Our objective is to describe the clinical and pathological findings of one case of advanced stage juvenile granulosa cell tumor in a woman following shortly after term pregnancy, whose antenatal period was free of any sonographically detectable tumor.

## CASE REPORT

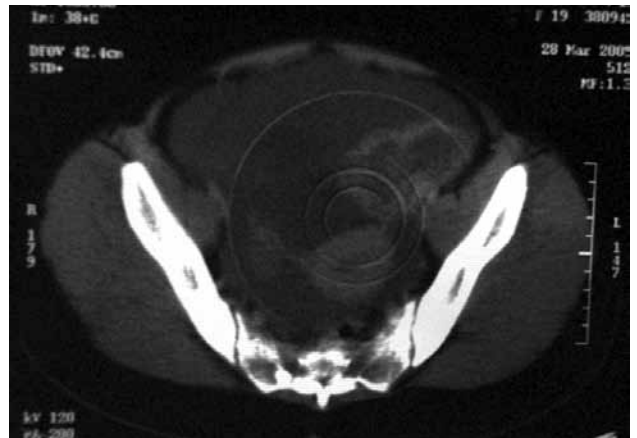
A 19-year-old woman presented with a one-month history of abdominal swelling and pain. She was gravida 1, parity 1 with a 1 year-old child. She delivered by cesarean section at 38th weeks of gestation. During her antenatal period, we did not observe any ovarian mass on ultrasonographic examinations. Upon admission to the emergency unit, she was referred to the radiology for an abdominal ultrasound examination which revealed 73x60 mm in diameter, heterogeneous, ill-defined bordered mass with solid and cystic components located in the left ovary (Figure 1, 2). Also massive intraabdominal ascite and heterogeneity on major omentum were found during abdominal tomography (Figure 3). CA-125 was slightly elevated to 39.9 U/mL (normal 35 U/mL). While inhibin was not ordered in pre-operative period, other tumor markers (CA19-9, CA15-3, AFP, CEA) were in normal limits. The patient underwent an exploratory laparotomy. At the surgical staging, eight liters of ascites was aspirated and a 10x9x9 cm in diameter, lobular, with papillary projections on surface and white-gray in color, heterogenous mass with solid and cystic components in the left ovary was found. Left salpingo-oophorectomy, partial omentectomy, removal of implants on peritoneal surfaces and peritoneal cytology were performed. Also during exploration, multicystic and firm nature of the right ovary was detected and wedge resection was performed. The rest of the abdomen, including all peritoneum was explored. Multiple intraabdominal metastases with <2 cm in diameter, on the peritoneal surfaces of bladder and douglas were excised. Partial omentectomy was also performed due to suspicious omental metastatic implants. The uterus and bilateral tubes were normal. The cell block on the ascitic fluid was positive for atypical cells. Pathological report confirmed the diagnosis of JGCT with all excised peritoneal materials were invaded by the tumor in addition to the mature adipose tissue observed on omentum. On microscopic examination, the neoplastic granulosa cells were lining cystic follicles and on immunohistochemical staining, inhibin activity was found to be positive. She was placed in FIGO stage IIIB. Six cycles



**Fig. 1.** A transvaginal ultrasonogram demonstrating a multi-locular tumor, measuring 7x6 cm in diameter, with dominant solid components and irregular margins.



**Fig. 2.** Tumoral mass exhibiting cystic features.



**Fig. 3.** Axial contrast-enhanced CT image of the lower abdomen and pelvis shows a mass with solid and cystic components in the left ovary. Note also intraabdominal massive ascite.

of chemotherapy was planned as adjuvant therapy and she is still under regular follow-up.

## DISCUSSION

Juvenile granulosa cell tumors (JGCTs), found in only 5% of all granulosa cell neoplasms, are rare ovarian tumors and it is important that all gynecologic oncologists should be aware of this rare tumor, its clinical presentation, and appropriate surgery.

Adnexal masses during pregnancy are relatively rare, with a reported incidence of 1/81 to 1/8,000 pregnancies.<sup>[3]</sup> Most of these adnexal masses disappear as the pregnancy progresses. Ultrasonography is often useful in detecting pelvic masses and distinguishing cystic and solid features. The ultrasonographic detection rate for adnexal masses during pregnancy is approximately 1%.<sup>[4]</sup> However, some adnexal masses are relatively difficult to diagnosed due to the mass itself, the imaging quality, or the experience of the sonographer.

Generally GCTs are characterized by a low malignant potential, local spread, late recurrences and a high survival rate. About 80% JGCTs occurring in children result in isosexual precocity. After puberty, the JGCTs usually present with abdominal pain or swelling. Likewise abdominal distension, as in our patient, due to the tumoral mass and ascite was the presenting symptom without any endocrinological abnormality.

The majority of JGCTs are unilateral and early stage tumors, whereas advanced stage JGCTs are not commonly encountered. Our patient was diagnosed in stage IIIB and the disease was progressed or occurred during the last one year of period. Since we performed routine ultrasonographic evaluations several times in antenatal period, we know that our case did not have any adnexial mass during her pregnancy. Advanced stage JGCTs reported in the literature were diagnosed after the beginning of symptoms so in these cases we do not have any knowledge regarding how long these tumors had been present. However we can consider that, in our patient the tumoral mass has been present or progressed or occurred for last one year of period, since it is now one year that the woman has delivered.

The primary management of JGCTs is surgical<sup>[5]</sup> and in young girls with stage IA disease, a unilateral salpingoophorectomy is performed, as the majority of the JGCTs are unilateral. At laparotomy, a careful inspection of the contralateral tube, intra-abdominal organs, and peritoneal surfaces, along with the sampling of pelvic plus paraaortic lymph nodes is recommended.<sup>[6]</sup> Since contralateral ovarian involvement is uncommon, wedge biopsy is not necessary if the ovary appears grossly normal. Complete primary surgical staging included at least a unilateral salpingoophorectomy with pelvic washings, peritoneal assessment, partial omentectomy, and pelvic and paraaortic lymph node sampling performed at initial surgery or within 3 months from the initial surgery were also recommended.<sup>[6]</sup> In the present patient, left salpingoophorectomy, partial omentectomy, wedge resection of right ovary, removal of implants on peritoneal surfaces and peritoneal cytology were performed and retroperitoneal lymph node sampling, though not performed, would have been appropriate.

Chemotherapy should be initiated promptly for women with stage IC to IV JGCTs after surgery. And the most commonly used regimen is a combination of bleomycin, etoposide, and cisplatin (BEP). Etoposide and cisplatin (EP); cyclophosphamide, doxorubicin, and cisplatin (CAP); platinum agent alone or taxanes also seem to be effective in sex cord stromal tumors of the ovary.<sup>[7]</sup> Radiotherapy, though not very effective, may be used for patients with advanced or recurrent JGCTs.<sup>[8]</sup> In the present case, she underwent BEP chemotherapy in our oncology department and she did not complete her planned chemotherapy, yet.

Although not reported in JGCTs, a limited number of recent studies have demonstrated a response to hormonal treatment in adult GCTs. For example, Freeman and Modesitt<sup>[9]</sup> reported two patients with recurrent adult GCTs responding to the aromatase inhibitor, anastrozole. Hardy et al.<sup>[10]</sup> also reported a patient with estrogen receptor-negative and progesterone receptor-positive GCT responding to megestrol and tamoxifen. Although these results are encouraging, all are limited number of studies in adult GCTs and we can not consider these reported treated cases as routine regimens.

GCTs are considered to be of low malignant potential and are characterized by their slow growth and late recurrence. Stage is clearly the most important prognostic factor. The reported 5-year survival rate for patients with stage I disease ranges from 75% to 90%. However advanced FIGO stages are associated with early relapses and poor outcome.<sup>[9]</sup>

A number of recent studies have evaluated the significance of prognostic factors in GCTs. In this regard, *gsp* oncogene (derived from *Gs* protein) and its products, activating the cAMP-dependent signalling and leading to abnormal cell proliferation, were demonstrated in 30% juvenile GCT cases.<sup>[10]</sup> In these *gsp*-positive patients, a more aggressive pattern were observed. Additionally, another predictor factor for JGCT survival was considered as Forkhead box L2 (FOXL2) protein.<sup>[11]</sup> In aggressive JGCTs, FOXL2 expression was found to be absent or decreased.<sup>[11]</sup> Unfortunately, we did not have any opportunity in our patient for evaluating the presence of these gene products and by this way for yielding the very aggressive and rapid progression of the mentioned tumor.

As a result, we can conclude that; although these tumors are seen in early stages and aggressive pattern is generally not expected, our patient was diagnosed at advanced stage and the disease can be accepted as occurred or progressed in only last one year. Due to this feature, as long as our knowledge, it was the first reported case regarding the occurrence history of the juvenile granulosa cell tumor in adult.

## REFERENCES

1. Rosai J, Ackerman LV. Female reproductive system. Surgical pathology. Edinburgh' Mosby 2004. p. 1692-5.
2. Hines JF, Khalifa MA, Moore JL, Fine KP, Lage JM, Barnes WA. Recurrent granulosa cell tumor of the ovary 37 years after initial diagnosis: a case report and review of the literature. *Gynecol Oncol* 1996;60(3):484-8.
3. Whitecar MP, Turner S, Higby MK. Adnexal masses in pregnancy: a review of 130 cases undergoing surgical management. *Am J Obstet Gynecol* 1999;181(1):19-24.
4. Bromley B, Benacerraf B. Adnexal masses during pregnancy: accuracy of sonographic diagnosis and outcome. *J Ultrasound Med* 1997;16(7):447-54.
5. Young RH, Scully RE. Sex cord stromal, steroid cell and other ovarian tumors. In: Kurman RJ, editor. *Blaustein's pathology of female genital tract*. 5th ed. New York: Springer; 2002. p. 917-21.
6. Abu-Rustum NR, Restivo A, Ivy J, Soslow R, Sabbatini P, Sonoda Y, et al. Retroperitoneal nodal metastasis in primary and recurrent granulosa cell tumors of the ovary. *Gynecol Oncol* 2006;103(1):31-4.
7. Brown J, Shvartsman HS, Deavers MT, Burke TW, Munsell MF, Gershenson DM. The activity of taxanes in the treatment of sex cord-stromal ovarian tumors. *J Clin Oncol* 2004;22(17):3517-23.
8. Wolf JK, Mullen J, Eifel PJ, Burke TW, Levenback C, Gershenson DM. Radiation treatment of advanced or recurrent granulosa cell tumor of the ovary. *Gynecol Oncol* 1999;73(1):35-41.
9. Calaminus G, Wessalowski R, Harms D, Göbel U. Juvenile granulosa cell tumors of the ovary in children and adolescents: results from 33 patients registered in a prospective cooperative study. *Gynecol Oncol* 1997;65(3):447-52.
10. Kalfa N, Ecochard A, Patte C, Duvillard P, Audran F, Pienkowski C, et al. Activating mutations of the stimulatory g protein in juvenile ovarian granulosa cell tumors: a new prognostic factor? *J Clin Endocrinol Metab* 2006;91(5):1842-7.
11. Kalfa N, Philibert P, Patte C, Ecochard A, Duvillard P, Baldet P, et al. Extinction of FOXL2 expression in aggressive ovarian granulosa cell tumors in children. *Fertil Steril* 2007;87(4):896-901.