



Polyp-confined Endometrial Serous Carcinoma Simultaneity with Cervical Adenocarcinoma: A Case Report

Soheila AMINIMOGHADDAM,¹ Marziyeh MOHAMMADI,¹ Saeid REZAEI²

¹Department of Obstetrics and Gynecology, Iran University of Medical Sciences, Firoozgar General Hospital, Tehran-Iran

²Student Research Committee, Iran University of Medical Sciences, Tehran-Iran

SUMMARY

The most common gynecologic cancer is endometrial adenocarcinoma, which presents mostly in postmenopausal women. There are two subtypes of endometrial cancer. Uterine serous carcinoma (USC) as a rare and aggressive type is associated with obesity and hypertension, and unlike the endometrioid type, is not associated with hyperestrogenism and atypical endometrial hyperplasia. Endometrial polyps would be a common finding in old women, and its likelihood with the presence of hypertension, tamoxifen therapy and obesity rises even more. Approximately 5.42% of the endometrial polyps contain the premalignant or malignant disease, but commonly, they are considered to be benign lesions. Serous carcinoma (USC) is less common malignant lesions in endometrial polyps. Concomitant endometrial cancers with cervical cancer in gynecologic oncology are very rare conditions, and to date, few cases have been reported. It even becomes rarer when we have a condition in which endometrial cancer is limited in the polyp. In this case, we report a cervical adenocarcinoma and simultaneous detection of endometrial serous carcinoma within the confines of polyp without the involvement of myometrium and other parts of the endometrium, which is unusual and rare. Treatment strategies in these cases are remaining controversial. Adjuvant therapy, radiation therapy and surgery have been debated, and everyone reported to be efficient in specific conditions. In our case, we decided to start adjuvant chemotherapy after surgical management, and fortunately, now, she is in good condition with well follow up results.

Keywords: Cervical cancer; endometrial serous adenocarcinoma; endometrial polyps.

Copyright © 2020, Turkish Society for Radiation Oncology

Introduction

The most common gynecologic cancer is endometrial adenocarcinoma, which presents mostly in postmenopausal women. There are two subtypes of endometrial cancer: type 1 with an endometrioid morphology and type 2, which represents only 10% of the cases but accounts for 39% of the mortalities.[1,2]

Uterine serous carcinoma (USC) as a rare and aggressive type, unlike the endometrioid type, is not asso-

ciated with hyperestrogenism and atypical endometrial hyperplasia. However, the endometrial intraepithelial carcinoma is found to be a precursor of it and its associated with high BMI and hypertension.[3,4]

The presentation of patients with USC is often with extrauterine disease despite minimally invasive involvement and has a poor prognosis in comparison with endometrioid type. Polyp-confined USC is a very rare form of uterine serous carcinoma.[3] The simultaneity of cervical cancer and endometrial cancer

Received: June 07, 2019
Accepted: August 27, 2019
Online: February 20, 2020

Accessible online at:
www.onkder.org

OPEN ACCESS This work is licensed under a Creative Commons Attribution-NonCommercial 4.0 International License.



Saeid REZAEI, MD
Student Research Committee,
Iran University of Medical Sciences,
Tehran-Iran
E-mail: rezaei.s@iums.ac.ir

is unusual.[5] In this case, we present a polyp limited USC in a patient with concomitant cervical cancer and discuss its features.

Case Report

A 64-year-old G6P6L6 female who referred to our hospital in Tehran with a pap test of an atypical glandular cells; favor neoplastic (AGC-FN) interpretation. Her first chief complaint was postmenopausal bleeding. She had no significant past medical history except for hypertension since 10 years ago. Her family history of cancer is negative and she is in a normal range of BMI (=20). The patient denies history of any STDs and use of alcohol and smoke and never received hormonal or tamoxifen treatment.

Due to an abnormal pap test, colposcopy was carried out and it was in favor of cervical adenocarcinoma. As the sonography showed an increase in endometrial thickness, we brought her to the operation room for hysteroscopy.

Macroscopically, there was a 3*2*2cm solid, cream-brown with tip hemorrhage polyp in the uterine cavity and in microscopic view the uterine cavity mass (Fig. 1); nearly total infiltrated by neoplastic tissue composed solid sheets (more than 50%) and atypical villoglular architectures and also atypic polymorphic giant nucleus cells. The patient underwent surgical management, including abdominal hysterectomy, bilateral adnexectomy, pelvic lymphadenectomy, omentectomy, appendectomy and pelvic washing.

Histologically, serous adenocarcinoma on polyp was seen, adenomyosis was not involved by carcinoma, and there were no signs of myoinvasion, lymphovascular and omentum involvement.

Immunohistochemically, endometrial mass sample for P16, P53, vimetin and PAX8 was positive with a high

ki67 index (>75%), while ER and WT1 were negative (Fig. 2).

According to findings and FIGO staging system (2015) and also pTNM staging (AJCC-2017), the tumor was considered as stage IA and chemotherapy was started for her with convenient results.

Discussion

Atypical glandular cell (AGC) in Papanicolaou (Pap) test interpretation for the detection of glandular neoplasia in the female genital tract is a challenging issue in gynecology. Although benign lesions are the most outcomes in the patients, high grade glandular neoplastic lesions of endometrium or cervix were seen in a significant subset of AGC cases. Importance of subcategory of AGC and age of patients in prognosticating the likely site of origin of the cervical lesion were discussed and noted in several studies. AGC-FN is more associated with glandular neoplasia and women of 50 or older ages are more identified to have endometrial carcinoma.[6,7]

In this case, we report a cervical adenocarcinoma and simultaneous detection of endometrial serous carcinoma within the confines of polyp without the involvement of myometrium and other parts of the endometrium, which is unusual and rare.

As the age of a woman advances above its fourth and fifth decades, endometrial polyps would be a common finding, and its likelihood with the presence of hypertension, tamoxifen therapy and obesity rises even more. Approximately 5.42% of endometrial polyps contain premalignant or malignant disease, but commonly, they are considered to be benign lesions.[2,4]

Endometrioid adenocarcinoma is the most common and uterine serous carcinoma (USC) is less com-

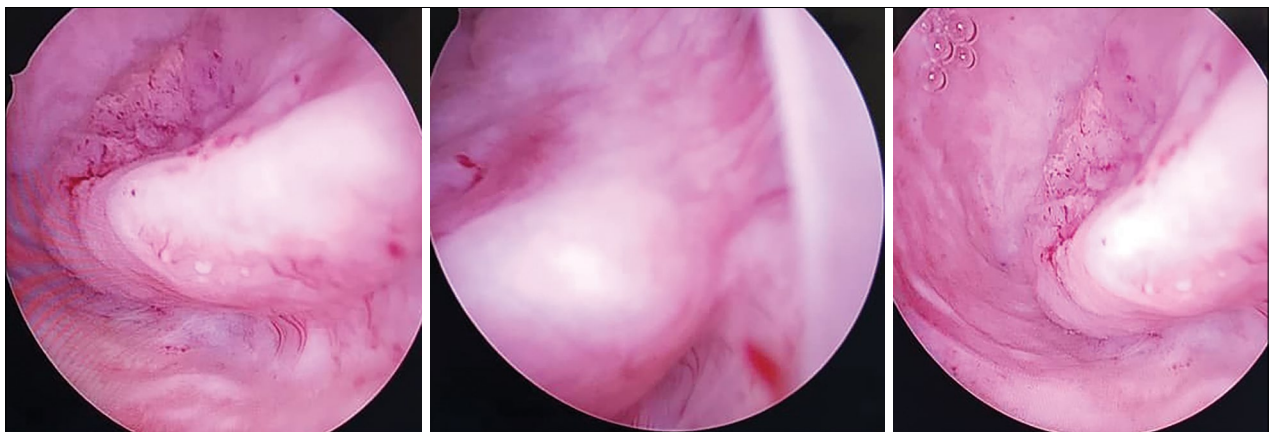


Fig. 1. Different views of polyp in hysteroscopy.

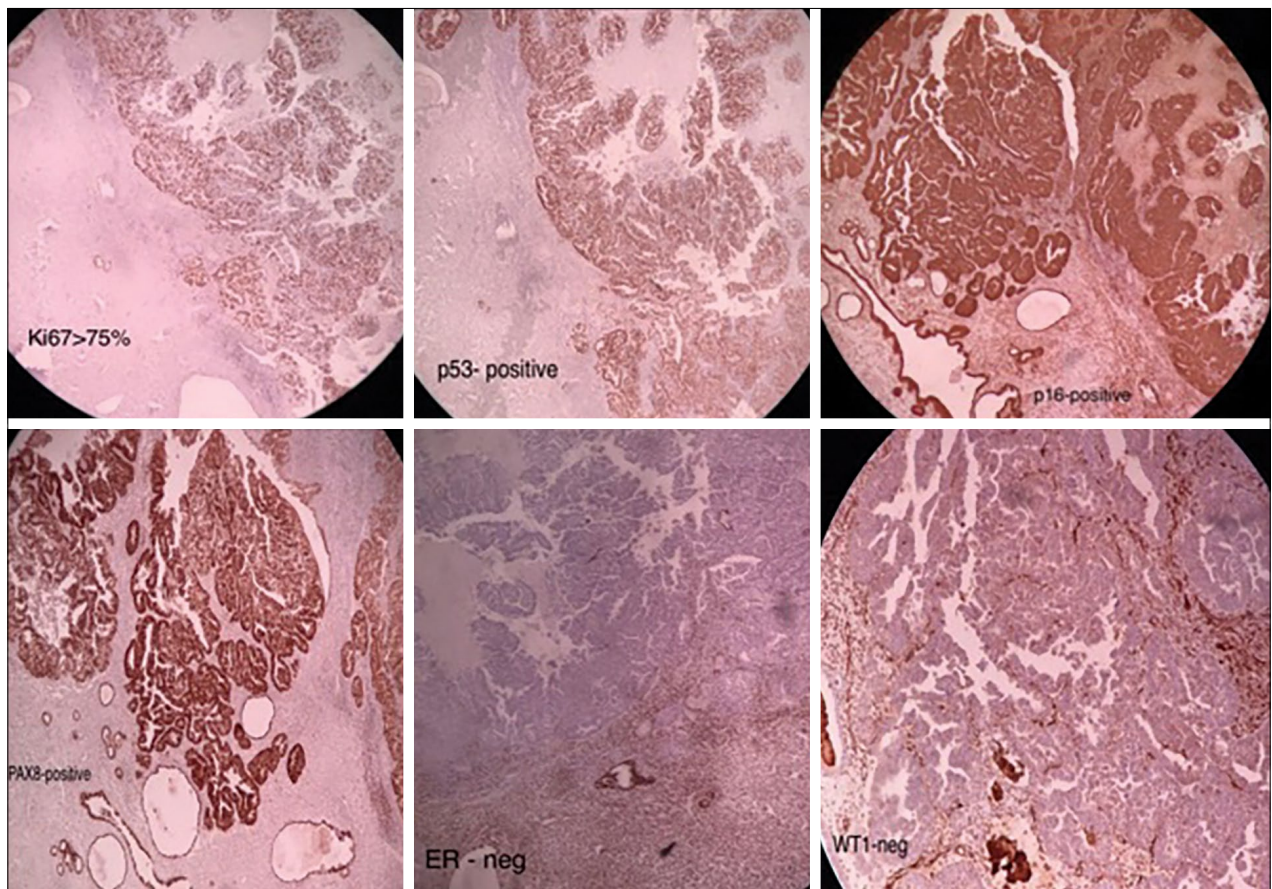


Fig. 2. The immunochemical photos of endometrial carcinoma.

mon malignant lesions in endometrial polyps. USC, as an aggressive cancer, has an increasing risk of recurrence and metastasis. Although estrogen and progesterone receptor positivity have been reported in the USC cases in few studies, they are negative in almost all USC cases. Thus, they are not responsive to hormone therapy. In contrast, USC cases almost always have strong reactivity for P53, as our present case has. [4] In a study, the value of immunohistochemistry and its factors for treatment ends and distinguishing different types of involvement in order of time and place were discussed, but it remains debatable in the majority of conditions. [8]

Concomitant endometrial cancers with cervical cancer in gynecologic oncology, are very rare conditions, and to date, few cases have been reported. [9] It even becomes rarer when we have a condition in which endometrial cancer is limited in polyp like our present case.

Cervical and endometrial cancers showed up usually with early symptoms, such as vaginal bleeding. Thus, they were often diagnosed in stage 1. Cervix and endometrium should be closely inspected when ab-

normal vaginal bleeding occurs. To be more accurate, the postoperative pathological examination should be carried out and staging before and after the operation is necessary for determining the type of treatment. [9]

Treatment strategies in these cases are remaining controversy. Adjuvant therapy, radiation therapy and surgery have been debated and everyone reported to be efficient in specific conditions. [2,3,7,10-14]

In our case, as we had a specific condition besides similarities to a few studies, in tumor board, some recommended starting radiotherapy because of cervical involvement. However, we decided to start adjuvant chemotherapy after surgical management, and fortunately, now, she is in good condition with well follow up results.

Conclusion

Gynecologists should be aware of the condition in which the endometrial polyps might have cancerous lesions without involvement of myometrium and other parts of the endometrium, besides simultaneous cervi-

cal adenocarcinoma should be considered. Strategy for treatment is controversial but adjuvant therapy after surgical management showed good results.

Informed consent: Written informed consent was obtained from the patient for publishing case report and images.

Peer-review: Externally peer-reviewed.

Conflict of Interest: There is no conflicts of interest.

Financial Disclosure: There is no source of support.

Authorship contributions: Concept – S.A.; Design – M.M, S.R.; Supervision – S.A.; Materials – None; Data collection &/or processing – M.M.; Analysis and/or interpretation – S.A., M.M.; Literature search – S.R.; Writing – S.R.; Critical review – S.A.

References

1. Dotto J, Tavassoli FA. Serous intraepithelial carcinoma arising in an endometrial polyp: a proposal for modification of terminology. *Int J Surg Pathol* 2008;16(1):8–10.
2. Hanley KZ, Fadare O, Fisher KE, Atkins KA, Mosunjac MB. Clinical Significance of Positive Pelvic Washings in Uterine Papillary Serous Carcinoma Confined to an Endometrial Polyp. *Int J Gynecol Pathol* 2016;35(3):249–55.
3. Ouyang C, Frimer M, Hou LY, Wang Y, Goldberg GL, Hou JY. Malignant Endometrial Polyps in Uterine Serous Carcinoma: The Prognostic Value of Polyp Size and Lymphovascular Invasion. *Int J Gynecol Cancer* 2018;28(3):524–8.
4. Bektaş S, Bahadır B, Barut F, Bayar Ü, Özdamar ŞO. Uterine Serous Carcinoma Arising From Endometrial Polyp: A Case Report. *Gynecology Obstetrics & Reproductive Medicine*. 2009;15(1):57–60.
5. Xu M, Zhou F, Huang L. Concomitant endometrial and cervical adenocarcinoma: A case report and literature review. *Medicine (Baltimore)* 2018;97(1):e9596.
6. Chhieng DC, Elgert P, Cohen JM, Cangiarella JF. Clinical significance of atypical glandular cells of undetermined significance in postmenopausal women. *Cancer* 2001;93(1):1–7.
7. Pradhan D, Li Z, Ocque R, Patadji S, Zhao C. Clinical significance of atypical glandular cells in Pap tests: An analysis of more than 3000 cases at a large academic women's center. *Cancer Cytopathol* 2016;124(8):589–95.
8. Giordano G. Value of immunohistochemistry in uterine pathology: common and rare diagnostic dilemmas. *Pathol Res Pract* 2009;205(10):663–76.
9. Lv S, Xue X, Sui Y, Du J, Zou J, Sun C, et al. Synchronous primary malignant neoplasms of the cervix and endometrium. *Mol Clin Oncol* 2017;6(5):661–4.
10. Ghoubara A, Price MJ, Fahmy MSE, Ait-Allah AS, Ewies A. Prevalence of hyperplasia and cancer in endometrial polyps in women with postmenopausal bleeding: A systematic review and meta-analysis. *Post Reprod Health* 2019;25(2):86–94.
11. Huang C, Hong MK, Ding DC. Endometrial adenomyoma polyp caused postmenopausal bleeding mimicking uterine malignancy. *Gynecol Minim Invasive Ther* 2017;6(3):129–131.
12. Idrees R, Din NU, Fatima S, Kayani N. Serous carcinoma arising in endometrial polyps: clinicopathologic study of 4 cases. *Ann Diagn Pathol* 2013;17(3):256–8.
13. Mandato VD, Torricelli F, Palomba S, Uccella S, Pirillo D, Ciarlini G, et al. Uterine Papillary Serous Carcinoma Arising in a Polyp: A Multicenter Retrospective Analysis on 75 Patients. *Am J Clin Oncol* 2019;42(5):472–80.
14. Trinh VQ, Pelletier MP, Echelard P, Warkus T, Sauthier P, Gougeon F, et al. Distinct Histologic, Immunohistochemical and Clinical Features Associated With Serous Endometrial Intraepithelial Carcinoma Involving Polyps. *Int J Gynecol Pathol* 2019.