



Effect of the Order of Adjuvant Treatment on the Cosmetic Results of Patients with Breast Cancer Treated with Breast-Conserving Surgery and Intraoperative Boost Radiotherapy

Semra GÜNAY,¹ Özge KANDEMİR,² Hakan TEZER,¹ Arzu Akan,¹ Orhan Yalçın¹

¹Department of Breast and Endocrine Surgery, SBU Okmeydanı SUAM General Surgery, Istanbul-Turkey

²Department of Radiation Oncology, SBU Okmeydanı SUAM, Istanbul-Turkey

OBJECTIVE

The aim of this study was to investigate the cosmetic outcome of adjuvant treatment after breast conserving surgery (BCS) and intraoperative boost radiotherapy (IOBRT) performed at the clinic over a 4-year period.

METHODS

A total of 65 patients who underwent at least 1 year of treatment for a diagnosis of early stage breast cancer were included in the study. Whole breast irradiation cases were included in Group A (n=34), and patients who underwent chemotherapy followed by WBI comprised Group B (n=31). Various details, including cosmetic outcome and score according to Johansen's scoring system were evaluated at postoperative month 1, after first treatment, and at the conclusion of 1 year of treatment.

RESULTS

The mean age of the patients was 53.5 years (range: 38-74 years), and the mean follow-up period was 23 months (range: 12-39 months). The mean tumor diameter was 16.95 mm (range: 4-30 mm). The tumor was located in the upper outer quadrant in 36 patients. It was determined that 14 patients had a comorbid disease, 7 were premenopausal, 7 were cigarette smokers, 7 had a tumor of >2 cm and 11 had inner quadrant localization. In 15 cases, the score was 9 or greater, indicating a poor cosmetic result. There were 7 patients with a poor cosmetic result in Group A, with a mean score of 10, and 8 patients from group B, with a mean score of 10.3. An independent t-test did not reveal a statistically significant difference between the groups ($p>0.1$).

CONCLUSION

The effects of radiotherapy and chemotherapy in addition to BCS and IOBRT in early breast cancer cases were similar with respect to cosmetic results. Smoking, comorbid disease, the size of the tumor and quadrant of localization may contribute to poor cosmetic outcome.

Keywords: Breast cancer; breast conserving surgery; chemotherapy; cosmetic outcome intraoperative radiotherapy; whole breast radiotherapy.

Copyright© 2018, Turkish Society for Radiation Oncology

Introduction

In the treatment of early-stage breast cancer, breast-conserving surgery (BCS) and conventional whole-breast

irradiation (WBI) together with tumor bed boost radiotherapy is considered the standard treatment.

One of the success criteria in breast cancer surgery, primarily for patients treated with BCS, is the cosmet-

Table 1 Severity of radiogenic changes of the scoring system of the skin, subcutaneous tissue and breast paranchyma according to the modified scoring system of Johansen et al [1]

Score	0	1	2	3
Telangiectasia	none	<1 cm	1-4 cm	>4 cm
Edema	none	<1 cm	1-4 cm	>4 cm
Hyperpigmentation	none	little	limited	common
Fibrosis	none	superficial	intense-limited	intense-common

ic result. This result depends on the experience of the treating surgeon, surgical technique, characteristics of the patient and the tumor, and local treatment methods such as systemic chemotherapy (CT) and WBI, as well as brachytherapy, accelerated partial irradiation and intraoperative radiotherapy (IORT).

This topic has been investigated in many studies, and in some series, the cases treated with both local and systemic methods have been studied together or separately. In this study, we aimed to investigate the effect of the order of adjuvant treatment on the cosmetic results of patients with breast cancer treated with BCS and IO boost RT (IOBRT) at our clinic during the last 4 years.

Materials and Methods

Sixty-nine patients treated with BCS+IOBRT because of breast cancer, with an elapsed time of at least 1 year after the end of treatment, were selected for this study. The patients were invited during the early period (within the first postoperative month), end of the first treatment (at the end of WBI or CT as the first treatment postoperatively and IOBRT), and late period (1 year after the completion of treatment). Informed consent was obtained from all patients. Patients with missing records because of various reasons (continuing treatment at another center and not consenting to participate in the study) were excluded from the study. Finally, 65 patients were included in the study. These patients were divided into two groups: Group A (n=34) included patients treated with WBI postoperatively, whereas Group B (n=31) included patients treated with CT followed by WBI.

Skin and tissue findings were recorded together with age, comorbidities, smoking status, menopausal status, tumor diameter, and location on the breast. The findings were scored according to the modified scoring system described by Johansen [1] (Table 1). Accordingly, those who received a score of 0–2 were evaluated as very good, 3–5 as good, 6–8 as moderate, and ≥ 9 as poor. The groups were compared by taking the average of the early

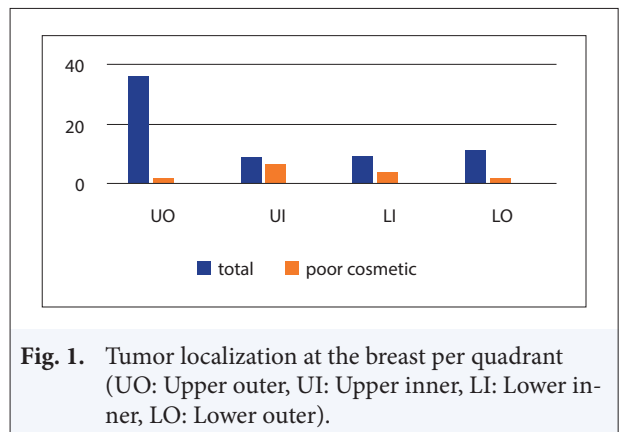


Fig. 1. Tumor localization at the breast per quadrant (UO: Upper outer, UI: Upper inner, LI: Lower inner, LO: Lower outer).

period, end of first treatment, and late period results of patients with poor cosmetic results.

Results

The mean age of the patients was 53.5 (38–74) years, the mean follow-up period was 23 (13–39) months, and the mean tumor diameter was 16.95 (4–30) mm. Seven patients were smokers and seven were premenopausal. The tumor was located on the upper outer quadrant in 36 patients, upper inner quadrant in 9, lower outer quadrant in 9, and lower inner quadrant in 11 (Fig. 1). The mean score of all patients was 4 (0–11). Twenty-one patients were evaluated as very good (33%), 18 as good (29%), 11 as moderate (18%), and 15 as poor (20%). (Fig. 2)

When the tumors and personal characteristics of the patients with poor cosmetic results (n=15) were examined, it was found that 4 were premenopausal and 11 were postmenopausal, similar the distribution of other cases in the series. Ten (71%) of the patients with comorbidities (n=14) and all smokers were in this group. While 7 of the 10 patients with a tumor diameter of >2 cm were in this group, it was interesting to note that the tumor was localized to the inner quadrant in 11 (73%) patients. Tumor was located in the upper inner quadrant in seven patients and lower inner quadrant in four. Smokers with a localization in the inner quadrant and a tumor diameter of >2 cm received higher scores (Table 2). Seven out of 15 (46%) patients with poor cosmetic results were in Group A, and these patients received WBI first and had a mean score of 10, whereas 8 (54%) patients were in Group B, and these patients received CT first and had a mean score of 10.3; six patients with a score of >10 points were in this group. It was noted that while the results of these 15 patients were defined as “poor cosmetics” according to the scoring system, the values obtained were just above the limit of 9 and that

Table 2 Poor cosmetic results (LI: lower inner, LO: lower outer, UI: upper inner, UO: upper outer)

Age/Menopause/ Comorbidity	Smoking/year	Tumour size	Loc at breast	Group	Early score	Intermed score	Late score	Median score
51/pre+	+/20	27	LI	A	11	10	8	10
49/post/-	-	10	UO	A	10	10	7	9
56/post/+	+/20/	27	UI	A	13	11	10	11
74/post/+	-	18	LI	A	13	8	6	9
66/post/+	+/10	10	UI	A	13	10	8	11
46/pre/-	-	22	UI	A	11	11	8	10
66/post/-	+/20	10	LI	A	11	9	9	10
62/post/+	+/15	15	LI	B	10	12	8	10
60/post/+	+/15	15	UI	B	13	11	9	11
55/post/-	-	23	UI	B	11	10	8	10
60/post/+	-	21	UO	B	12	9	8	10
47/pre/-	+/5	30	LO	B	13	10	10	11
49/post/+	-	15	UI	B	12	11	9	11
57/post/-	-	18	LO	B	8	11	8	9
41/pre/+	-	18	UI	B	8	11	10	10

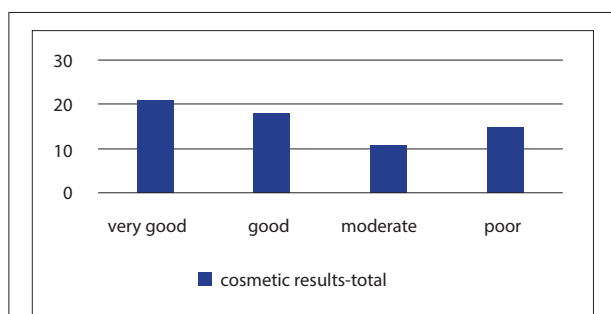


Fig. 2. Cosmetic results.

the first and intermediate scores were higher and the late results were lower (Table 2). When the groups were compared, it was observed that age, menopausal status, applied treatment, and order of treatment did not make a difference. According to the independent sample t-test, there was no statistically significant difference between the groups ($p>0.1$).

Discussion

Breast cancer is an increasingly common public health problem, and its prevalence has been reported to be increased by 3.1% from 1980 to 2010 [2]; however, significant changes have taken place in the treatment of breast cancer. Radical interventions have been replaced by minimally invasive and effective approaches, which take quality of life into account. While BCS and RT are considered the standard therapy in early-stage breast cancer, the frightening tumor recurrence most commonly oc-

curs in the tumor bed. Irradiation of the tumor bed, i.e., boost RT, in addition to surgery and subsequent WBI reduces the risk of local recurrence by up to 40% and contributes to disease-free survival and overall survival. [3] Boost RT can be performed intraoperatively as well as externally after WBI postoperatively. The most important difference between these two procedures is the possibility that the postoperative external boost RT may not precisely focus on the tumor bed. Relocation of the tumor bed due to different surgical techniques and oncologic approaches or hematoma, seroma, and fibrosis, which can occur during the wound healing process, can be considered as the causative factors for this situation. IOBRT allows direct irradiation of the tumor bed without encountering tissue changes that occur postoperatively, i.e., without disturbing the tissue structure and focusing directly on the tumor bed.[1,3]

The role of other treatment modalities on cosmetic results after breast surgery has been addressed in many studies. In some series, the effect of systemic treatment on cosmetic results, in some cases radiotherapy techniques, and in others both local and systemic treatments have been discussed. While in early studies long-term cosmetic results were solely based on visual evaluation, it is reported in recent publications that the cases are examined using different scales. The most detailed of these is the Radiotherapy Oncology Group (RTOG) scale that carries the same name. It is suitable for prospective studies and especially studies on RT techniques. In our series, because the patients were scored both in terms of the order of RT and CT they received and by physician

examinations, the scoring system described and used by Johansen was preferred with the assumption that it would be more objective.[1,4] Johansen et al. prospectively studied 266 patients using the DBCG-82 protocol and investigated the local effects of RT and whether the added CT increased these changes. Among these patients, 94 received CT and the mean follow-up time was 6.6 years. Cosmetic results were scored according to the scoring system described by the author, and the effects of RT alone and together with CT were found to be similar. It has been reported that patients with poor cosmetic results having a tumor diameter of >2 cm accompanied by axillary dissection also exhibited personal characteristics such as smoking and presence of comorbidities.[4] In our study, all smokers and those with comorbidities were also found to achieve higher scores.

Recht reviewed prospective and retrospective studies of patients treated with BSC+RT and systemic treatment and concluded that although there was no consensus on early and late effects, the predominant view was that cosmetic results are not related to systemic treatment.[5] In our series, there was no significant difference despite a slight increase in the score of patients treated with CT compared with those who were not. In another series, 56 patients treated with BCS + IORT with a tumor size of <3 cm were evaluated. Among these patients, 45 received IORT alone and 11 received additional postoperative WBI, and after a time period of at least 1 year after the end of treatment, the follow-up results with a mean follow-up of 3.1 years were scored by the patients and neutral physicians according to the RTOG scale. In this study, patients who received IORT alone were evaluated as good and excellent and 11 patients with additional WBI were evaluated as good and moderate and very few were evaluated as poor.[6] The results of this study have been examined using a different scale, but they are similar with those of our study because 80% of the patients received IORT.

In the article by Kelemen wherein 178 patients receiving CT+RT after BCS were investigated, the outcomes of patients at 1 and 5 years were evaluated according to the RTOG scale and it was concluded that the effect of RT on the breast was greatly diminished due to new technologies. In this series, only 20 patients received CT and the treatment did not make a difference in terms of cosmetic results. In general, poor cosmetic results were associated with age (>50 years), tumor size (>2 cm), presence of comorbidities, tumor location in the breast, and other factors of the patient (smoking and N+ status).[7] In our series, the location and the diameter of the tumor were also found to be important factors.

In 75% of the patients with poor cosmetic results, the tumor was localized to the inner quadrant where there is poor blood supply to the scanty breast tissue.

IOBRT has also been the subject of many studies in terms of its relation to cosmetic results as an independent factor. Boost RT is also remarkable because it requires additional doses as well as it significantly reduces the risk of local recurrence. As opposed to postoperative boost RT, IOBRT is advantageous because it allows focusing directly on the tumor bed and can be delivered with less but more effective dose without skin toxicity and has also been shown to be superior in terms of cosmetic results and patient comfort.[8,9] The optimal dose of WBI with IORT is being investigated by two ongoing multicenter prospective studies. The initial results of these studies indicate that the 3-week WBI added to IORT during surgery is sufficient and favorable. In appropriate cases, IOBRT provides advantages in terms of personal and institutional cost along with its favorable effects on tissue tolerance and cosmetic results by reducing late effects of RT.[10,11]

According to ESTRO 2016, 50 patients with breast cancer undergoing IOBRT (10 Gy) using MOBETRON between 2008 and 2011 were presented. These patients additionally received 50 Gy WBI and those in whom CT was indicated received postoperative CT followed by WBI. In this study, which is similar to our series in terms of treatment schedule, the observation period was 1.5–5.5 years and cosmetic results were evaluated by EORTC questionnaires (QLQ-C30 and QLQ-BR23) at 6 months, 1 year, 2 years, 3 years, and 4 years after the end of RT, and it was found that the early (first year) local effects of IORT were easily tolerated and its effect on cosmetic results were not statistically significant ($p=0.08$).[12]

In another study investigating the effect of different boost techniques on cosmetic results, it was reported that IOBRT was better tolerated than postoperative external boost RT, and it did not have any negative effects on skin change.[13] In another study investigating the effects of IOBRT, 75 patients with early-stage breast cancer underwent BCS and IOBRT using MOBETRON, followed by WBI. Seventy-four patients received CT, and approximately 90% of the patients were evaluated as very good and good after a mean follow-up period of 50 months.[14]

Because IOBRT is not present in all studies in the literature investigating the effects of systemic and local treatments, it is still debated whether this practice is an independent factor of cosmetic results. The studies conducted solely for this purpose are recent and limited, and the existing studies generally indicate a positive effect.

All the patients presented in this study were selected among those in whom IOBRT was performed during BCS. Although the time elapsed since the first treatment of all patients was 50 months, because we studied patients with at least 1 year after the end of the adjuvant treatment, the mean follow-up period of the scored patients was 25 (13–39) months. Although ≥ 23 months of follow-up is sufficient to observe the late effects of both systemic treatment and RT, whether IOBRT is an independent factor for cosmetic results or not should be evaluated in broader series.

Conclusion

In patients in whom only postoperative WBI is performed after BCS and IOBRT because of breast cancer and in patients who received CT followed by WBI, the characteristics of the patients and the tumor were responsible for cosmetic results, and it was observed that 15 patients with poor cosmetic results had different characteristics than the remaining cases in the series such as smoking, presence of comorbidities, and large tumors localized to the inner quadrant.

The effects of treatment modalities applied during and after surgery and the order of these modalities on breast esthetics were found to be similar, and no statistical difference was found ($p > 0.1$).

Peer-review: Externally peer-reviewed.

Conflict of Interest: None declared.

Authorship contributions: Concept – S.G., Ö.K.; Design – S.G., A.A.; Supervision – S.G., Ö.K.; Materials – S.G., Ö.K., H.T.; Data collection &/or processing – H.T.; Analysis and/or interpretation – S.G., O.Y., A.A., Ö.K.; Literature search – S.G.; Writing – S.G.; Critical review – S.G., O.Y.

References

1. Johansen J, Overgaard J, Rose C, Engelholm SA, Gadeberg CC, Kjaer M, et al. Cancer Cooperative Group (DBCG) and the DBCG Radiotherapy Committee. Cosmetic outcome and breast morbidity in breast-conserving treatment--results from the Danish DBCG-82TM national randomized trial in breast cancer. *Acta Oncol* 2002;41(4):369–80. [CrossRef]
2. Forouzanfar MH, Foreman KJ, Delossantos AM, Lozano R, Lopez AD, Murray CJ, et al. Breast and cervical cancer in 187 countries between 1980 and 2010: a systematic analysis. *Lancet* 2011;378(9801):1461–84.
3. Reitsamer R, Peintinger F, Kopp M, Menzel C, Kogelnik HD, Sedlmayer F. Local recurrence rates in breast cancer patients treated with intraoperative electron-boost radiotherapy versus postoperative external-beam electron-boost irradiation. A sequential intervention study. *Strahlenther Onkol* 2004;180(1):38–44. [CrossRef]
4. Johansen J, Overgaard J, Overgaard M. Effect of adjuvant systemic treatment on cosmetic outcome and late normal-tissue reactions after breast conservation. *Acta Oncol* 2007;46(4):525–33. [CrossRef]
5. Recht A. Integration of systemic therapy and radiation therapy for patients with early-stage breast cancer treated with conservative surgery. *Clin Breast Cancer* 2003;4(2):104–13. [CrossRef]
6. Kimple RJ, Klauber-DeMore N, Kuzmiak CM, Pavic D, Lian J, Livasy CA, et al. Cosmetic outcomes for accelerated partial breast irradiation before surgical excision of early-stage breast cancer using single-dose intraoperative radiotherapy. *Int J Radiat Oncol Biol Phys* 2011;79(2):400–7. [CrossRef]
7. Kelemen G, Varga Z, Lázár G, Thurzó L, Kahán Z. Cosmetic outcome 1-5 years after breast conservative surgery, irradiation and systemic therapy. *Pathol Oncol Res* 2012;18(2):421–7. [CrossRef]
8. Günay S, Alan Ö, Yalçın O, Türkmen A, Dizdar N. Our intraoperative boost radiotherapy experience and applications. *Ulus Cerrahi Derg* 2015;32(1):30–6.
9. Sedlmayer F, Reitsamer R, Wenz F, Sperk E, Fussl C, Kaiser J, et al. Intraoperative radiotherapy (IORT) as boost in breast cancer. *Radiat Oncol* 2017;12(1):23.
10. Juneja P, Bonora M, Haviland JS, Harris E, Evans P, Somaiah N. Does breast composition influence late adverse effects in breast radiotherapy? *Breast* 2016;26:25–30. [CrossRef]
11. Eldredge-Hindy HB, Rosenberg AL, Simone NL. Intraoperative radiotherapy for breast cancer: the lasting effects of a fleeting treatment. *Int J Breast Cancer* 2014;2014:214325. [CrossRef]
12. Urbanski B, Roszak A, Bratos K, Milecki P, Karczewska-Dzionk A, Litoborski M, et al. EP-1150: Patient quality of life treated with IORT during BCS followed by whole breast radiotherapy (WBI). *Radiother Oncol* 2016;19(Suppl 1):S549. [CrossRef]
13. Vass S, Bairati I. A cosmetic evaluation of breast cancer treatment: a randomized study of radiotherapy boost technique. *Int J Radiat Oncol Biol Phys* 2005;62(5):1274–82. [CrossRef]
14. Yu W, Lin Z, Ju ZJ, Li XR, Zhang YJ, Kong QL, et al. Intraoperative radiation therapy delivered prior to lumpectomy for early-stage breast cancer: a single institution study. *Am J Cancer Res* 2015;5(7):2249–57.